

Case Reports

Radicular Cyst associated with maxillary molar and sinus – A case report with mini review of literature

Sahana A¹, Ashok KP²

¹Department of Oral and Maxillofacial Pathology, ²Department of Periodontics and Implantology, GSL Dental College & Hospital, Rajahmundry, Andhra Pradesh, India

ABSTRACT:

Radicular cysts or Root end cyst are known to be the most common odontogenic cyst of the jaws. They comprise about 60% of jaw cysts and 15% of all periapical lesions. Epithelium at the apex of a nonvital tooth, usually the cell rests of Malassez (also could be crevicular epithelium, sinus lining or sinus tract lining) can be stimulated by inflammation to form this true cyst. This report describes a case of a radicular cyst occurring in a 40 years old female involving posterior maxillary region extending to the maxillary sinus area.

KEYWORDS: Nonvital teeth, odontogenic cyst, Periapical cyst, Enucleation

Address for correspondence : Address for correspondence : Dr. Sahana A, Associate Professor, Department of Oral and Maxillofacial Pathology, GSL Dental College & Hospital, Rajahmundry, Andhra Pradesh, India, E-mail: sahanarr@yahoo.com
Submitted: 26.08.2023, Accepted: 04.12.2023, Published: 26.12.2023

INTRODUCTION:

Cyst is a common pathological lesion and can occur anywhere in the body. Cysts of oral and paraoral region are usually derived from odontogenic apparatus, their remnants or epithelium entrapped in the line of fusion during development of various facial processes. Cysts of orofacial region are broadly classified under the following categories - Odontogenic, Non-odontogenic and Miscellaneous. The radicular cyst is an example of inflammatory odontogenic cyst^[1]

Radicular cyst (RC) is the most common inflammatory cyst seen at the apices of a grossly decayed or a non-vital tooth. This arises from the epithelial residues (cell rests of Malassez) in the periodontal ligament space². Simon in 1980 showed that RC is of two types – true RC which contains a closed cavity entirely lined by epithelium and periapical pocket cyst or bay cyst which has epithelial lining attached to the margins of the apical foramen in such a way that decayed tooth root canal is open to cystic lumen. As the true RC is completely enclosed it is “self-sustaining” and is more likely to remain behind in

the jaw after the removal of offending tooth, which is referred to as residual cyst. Other similar lesions are inflammatory collateral cyst or periodontal cyst (seen at cervical margin of the lateral aspect of a root), [Figure 1] paradental cyst (lateral aspect of partially erupted mandibular third molar root) and mandibular infected buccal cyst (buccal surfaces of mandibular molars)^[2].

PATHOGENESIS :

Inflammatory cysts of jaws arise as a result of epithelial proliferation within an inflamed tissue which could be due to a physical, chemical or bacterial injury.³ Generally, pulp inflammation is a sequel of dental caries. Bacteria from gingival sulci or periodontal pockets^[4] reach the pulp tissue through exposed dentinal tubules or gap cement-enamel junction at the cervical area of a tooth.⁵ Seeding of microbes through blood stream into the necrotic pulp also contributes (anachoresis)^[6]. Polymicrobial community of anaerobic flora flourish in the selective habitat of the

This is an open access journal, and articles are distributed under the terms of the Creative Commons Attribution-Non Commercial ShareALike 4.0 License, which allows others to remix, tweak, and build upon the work non-commercially, as long as appropriate credit is given and the new creations are licensed under the identical terms.
For reprints contact: editor.pjsr@peoplesuniversity.edu.in

How to cite this article: Sahana A & Ashok KP. Radicular Cyst associated with maxillary molar and sinus – A case report with mini review of literature. PJSR. 2023;16(2):26-30.

Access this article online

Quick Response Code:



Website:

www.pjsr.org

DOI:

doi.org/10.5281/zenodo.10432070

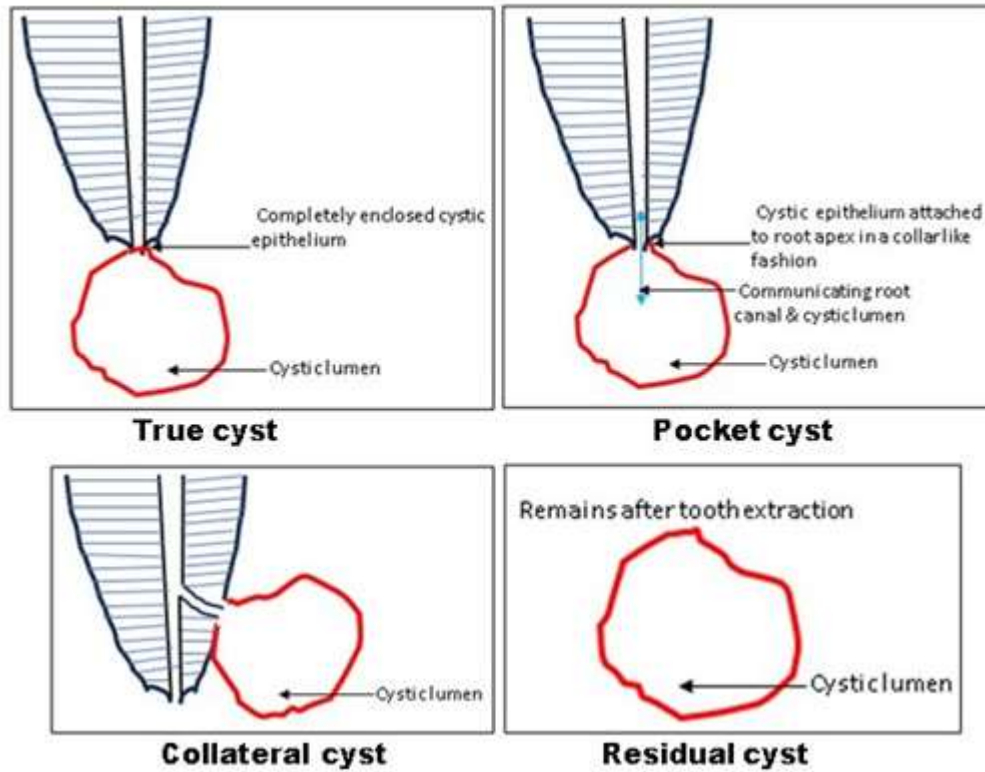


Figure 1: Schematic diagram representing the types of radicular cyst.

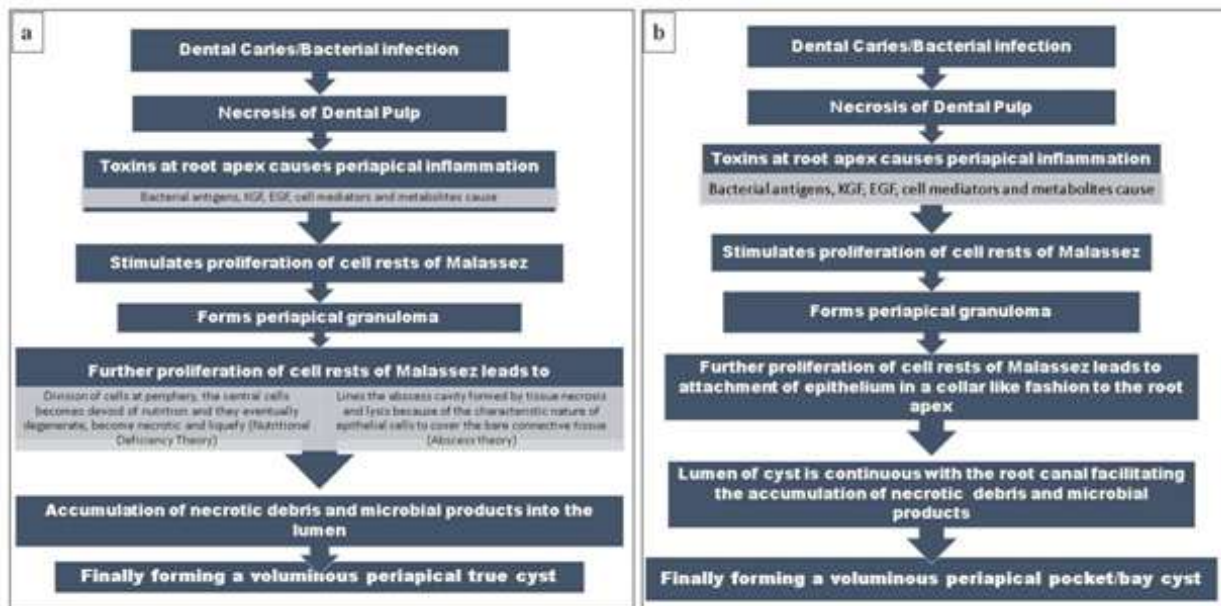


Figure 2a & b: Flowchart representing the pathogenesis of periapical true cyst and bay cyst respectively.

root canal. These microbes exhibit various biological and pathogenic properties like antigenicity, mitogenic activity, enzymatic histolysis, chemotaxis and activation of host cells. As the microbial invaders reach the apex of tooth, they encounter the host defence forces and clash, leading to destruction of periapical tissue.

Further, this continues and can form several categories of periapical lesions. Such chronic lesions can develop a periapical cyst, but not every chronic lesion develops into a cyst.^[5,7][Figure 2a & b]

Though, RCs are inflammatory odontogenic cysts they are painless and asymptomatic and are often

said to be painless unless infected. Therefore, most of the times the radiographic investigations of nonvital teeth leads to diagnosis of asymptomatic radicular cysts. Initially the swelling is bony hard. In later stages it exhibits 'springiness' or 'egg shell crackling' of the surrounding bone. As the cyst becomes more chronic and increases in size the bone gets completely eroded and swelling becomes fluctuant.^[8]

RC is most commonly seen in males, with a male predilection (M:F 1.6:1) and age range of 30-50 years in the maxillary anterior region⁸. This present case is an unusual presentation of radicular cyst which does not have the above-mentioned common features.

CASE REPORT :

A 40 years old female patient came to our institution with a swelling in the left upper back region of jaw. She gave a history of mild pain in swelling for 2 months which aggravated since 15 days. She took medicines given by local pharmacist which relived the pain for few hours and then continued with same intensity.

Solitary swelling over the left upper third of the face, size approximately 2.5 × 2.0 cm, oval in shape, extending anteriorly to obliterate the nasolabial fold.

superiorly till the lower border of eye, the borders were ill-defined and the skin over the swelling appear normal. On palpation, all inspectory findings in relation to the site, size, shape, border, skin over the swelling were confirmed with a mild rise in local temperature and soft to bony hard consistency.

Intraorally, the swelling was tender, soft to hard in consistency and drainage of salty fluid at the root stumps of left first maxillary molar. There was no oro-antral communication noted.

Radiographically, orthopantomograph and CBCT of the area showed a unilocular radiolucent lesion associated with root stumps of 26 with ill-defined borders measuring about 1.5 cm × 2 cm within the jaw. Superiorly, it was extending in to the maxillary sinus. Based on the clinical, radiographic and 3D construction image, provisional diagnosis of radicular cyst was made (Fig 3a, b & c).

FNAC (fine needle aspiration cytology) was done on the day of visit (Fig 4a & b). Extraction of root stumps and cystic enucleation under local anaesthesia was planned. The cystic lining was enucleated and was preserved for histopathology examination. After the bleeding was controlled, the flap was sutured back and primary closure was achieved.

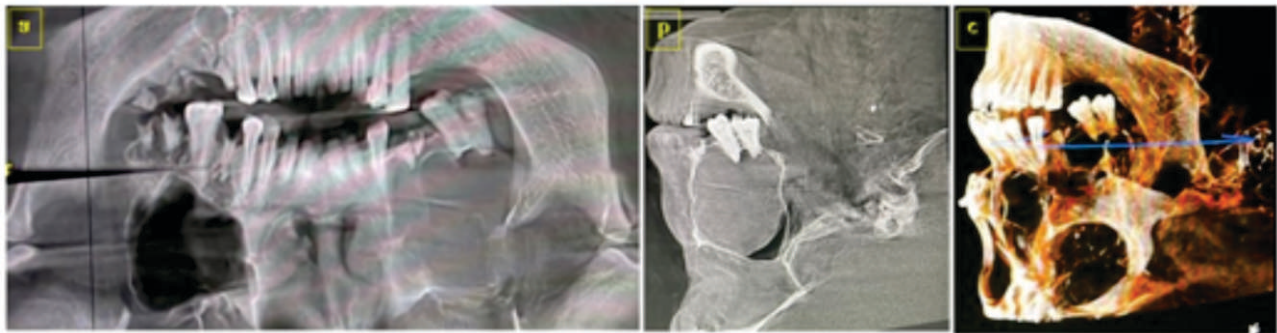


Figure 3a, b & c : OPG, CBCT and 3D construction image showing the involvement of lesion from periapical area to the maxillary sinus.

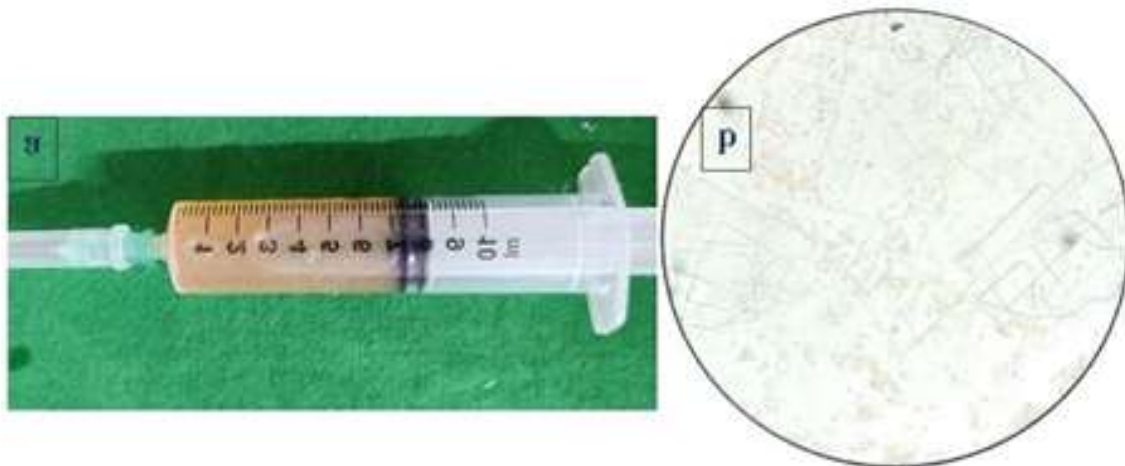


Figure 4a & b : "Shimmering Gold" effect seen in fluid collected from FNAC of lesion and cytology of the same showed cholesterol crystals.

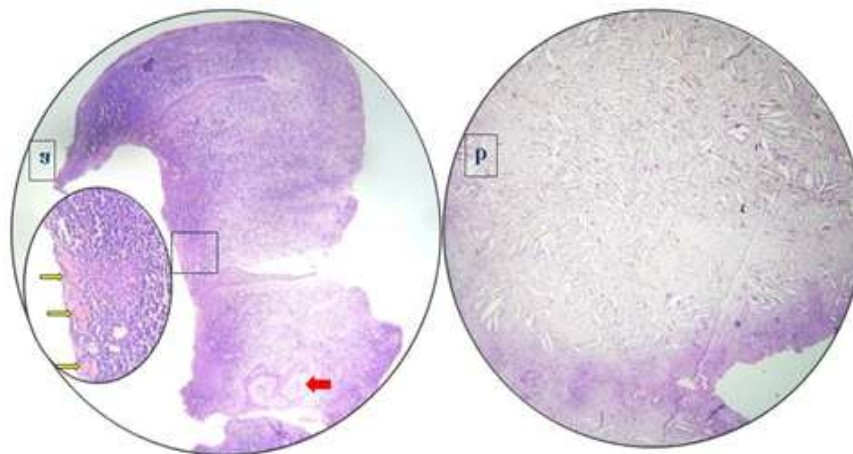


Figure 5a & b: Microscopically arcading pattern of epithelium (red arrow), Rushton bodies(yellow arrows) & Cholesterol clefts

Microscopic examination of a haematoxylin & eosin-stained sections revealed a cystic lumen lined by nonkeratinized stratified squamous epithelium in arcading pattern. Focal area also showed presence of pseudostratified ciliated columnar epithelium. The underlying fibrous connective tissue showed infiltration of mixed inflammatory cells, cholesterol clefts, haemorrhagic areas, hemosiderin pigments and dilated blood vessels with engorged RBC's (red blood cells) in its lumen (Fig 5a & b). Regular follow-up after every 6 months was done and patient is asymptomatic post treatment.

DISCUSSION:

RCs are amongst the most common cystic lesions of the jaw. They develop as a result of inflammatory processes within the root canal system of a tooth, leading to pulpal necrosis.^[9] Patient often complains of slowly enlarging swellings. A sine qua non for the diagnosis of a RC is the related presence of a tooth with a non-vital pulp.^[10]

According to Mass et al^[5] the prevalence rate of radicular cysts associated with primary molars is probably higher compared permanent molars. It is possible that, unlike cysts of permanent dentition, primary teeth are extracted but not submitted for pathological examination, a fact that may account for the low estimation of the real frequency of cysts associated with primary teeth.^[11]

Radiographically, most RCs appear as round or pear shaped unilocular radiolucent lesions in the periapical region. The cysts may also displace or cause mild root resorption of adjacent teeth. Involvement of maxillary sinus is rare. Our case showed extension of cyst in the sinus cavity. Distinguishing between granuloma and a cyst is impossible, although some say that if the lesion larger than 2 cm is more likely to be a cyst.^[12]

The surgical approach to this cyst is either marsupialization or enucleation. The treatment of choice is dependent on the size and localization of the lesion, the bone integrity of the cystic wall and its proximity to vital structures. In case of RC associated with primary teeth conservative treatment is planned to save the underlying permanent tooth bud and monitoring the eruption of the tooth.⁸ Follow up is highly recommended considering the recurrence rate of the lesion. Through correct treatment, prognosis is usually promising.^[13]

CONCLUSION:

Careful clinical examination combined with thorough imaging modalities to evaluate the general aspects of this lesion is important as, it is asymptomatic in nature and goes undiagnosed most of the times. The complete case details along with histopathological confirmation of the diagnosis will guide for the selection of the best treatment plan. Proper treatment and long-term follow are recommended as occasionally neoplastic transformations of the epithelial lining of RCs are noted.

Financial Support and sponsorship

Nil.

Conflicts of interest

There are no conflicts of interest.

REFERENCES:

1. Sivapathasundharam B. Shafer's Textbook of Oral Pathology. 9th Edn . New Delhi: Elsevier; 2020. p.71-2.
2. Azad A, Chourasia HR, Singh D, Sharma I, Azad A, Pahlajani V. Management of a Large Periapical Cyst: A Case Report. PJSR. 2014 7(1):47-50. doi.org/10.5281/zenodo.8255734

3. Latoos S, Shah AA, Jan SM, Qadir S, Ahmed I, Purra AR, Malik AH. Radicular Cyst. JK Science. 2009;11:187-9.
4. Grossman LI. Origin of microorganisms in traumatized, pulpless, sound teeth. J Dent Res. 1967 May-Jun;46(3):551-3. doi: 10.1177/00220345670460031601. PMID: 4961087.
5. Nair PN. Pathogenesis of apical periodontitis and the causes of endodontic failures. Crit Rev Oral Biol Med. 2004 Nov 1;15(6):348-81. doi: 10.1177/154411130401500604. PMID: 15574679.
6. Allard U, Nord CE, Sjöberg L, Strömberg T. Experimental infections with *Staphylococcus aureus*, *Streptococcus sanguis*, *Pseudomonas aeruginosa*, and *Bacteroides fragilis* in the jaws of dogs. Oral Surg Oral Med Oral Pathol. 1979 Nov;48(5):454-62. doi: 10.1016/0030-4220(79)90078-1. PMID: 114906.
7. Takahashi K. Microbiological, pathological, inflammatory, immunological and molecular biological aspects of periradicular disease. Int Endod J. 1998 Sep;31(5):311-25. doi: 10.1046/j.1365-2591.1998.00171.x. PMID: 9823133.
8. Mukherjee D. Radicular cyst involving anterior region of mandible -A case report. International Journal of Applied Dental Sciences 2020;6(2):359-61.
9. S Tootla, V Premviyasa, V Yengopal, D Howes, Nikita Morar. Radicular cyst: Atypical presentation and therapeutic dilemma. SADJ 2017;72(8):379-82.
10. Nainani P, Sidhu GK. Radicular Cyst –An Update with emphasis on Pathogenesis. J Adv Med Dent Scie Res 2014;2(3):97-101.
11. Penumatsa NV, Nallanchakrava S, Muppa R, Dandempally A, Panthula P. Conservative approach in the management of radicular cyst in a child: case report. Case Rep Dent. 2013;2013:123148. doi: 10.1155/2013/123148. Epub 2013 Feb 17. PMID: 23476812; PMCID: PMC3588395.
12. Narula H, Ahuja B, Yeluri R, Baliga S, Munshi AK. Conservative non-surgical management of an infected radicular cyst. Contemp Clin Dent. 2011 Oct;2(4):368-71. doi: 10.4103/0976-237X.91806. PMID: 22346170; PMCID: PMC3276870.
13. Bacholkar SA, Navalkar A. Pushing diagnostic boundaries of an infected radicular cyst –an unusual case report. International Journal of Recent Scientific Research 2022;13(4):998-1002. DOI: <http://dx.doi.org/10.24327/ijrsr.2022.1304.0215>