

Efficacy of Temporalis Myofascial Flap as an Interpositional Graft Material in the Management of TMJ Ankylosis:

K. Rajanikanth, M. K. Gupta, Pramod Sharma, Ajay Pillai, Kanishk Guru

Department of Oral & Maxillofacial Surgery, People's Dental Academy, People's Campus Bhanpur, Bhopal-462037 (M.P.)

Abstract:

Temporo-mandibular joint (TMJ) ankylosis is an extremely disabling affliction that causes problems in mastication, digestion, speech, appearance and hygiene. Surgery of TMJ ankylosis needs careful evaluation and planning to yield predictable results. Ankylosis may be corrected surgically by an array of procedures like gap arthroplasty, joint reconstruction and interpositional arthroplasty. Though many types of autogenous grafts and alloplastic materials are available for the interpositioning, the temporalis muscle graft offers significant advantages like ease of harvesting, minimal donor site morbidity and effective coverage of the arthroplasty site. The efficacy of the same is highlighted in this article by its application in four cases of TMJ ankylosis.

Key Words: Temporo-mandibular joint ankylosis, interpositional arthroplasty, TMJ surgery, temporalis muscle, temporal fascia.

Introduction:

Ankylosis may be defined as the fusion of joint surfaces by bone or fibrous tissue (*ANKYLOSIS* = stiff joint, *Greek word*). Temporo-mandibular joint (TMJ) ankylosis can cause asymmetry resulting in severe facial disfigurement as well as difficulties in eating, breathing and speech. Should it occur before facial growth is completed, ankylosis produces micrognathia, especially if the disease is bilateral.

Temporo-mandibular joint ankylosis may be classified by a combination of location (intra or extra articular), type of tissue involved (bony, fibrous, or fibro-osseous) and extent of fusion (complete or incomplete). Kazanjian (1955) classified ankylosis as true and false. Any condition that gives rise to osseous or fibrous adhesion between the surfaces of the temporo-mandibular joint is a true ankylosis. False ankylosis results from pathological conditions not directly related to the joint. Various factors can cause TMJ ankylosis, including trauma, systemic and local infections, and neoplasm in the area. Laskin (1976) reported a higher incidence of post-traumatic ankylosis in children.

Management of TMJ ankylosis is through surgical intervention as soon as the condition is

recognized. Early surgery can minimize the severity of the restriction of facial growth. The basic techniques for surgical correction of ankylosis include the *gap arthroplasty* (resection of the bony mass without interpositional material); *joint reconstruction* (resection of the bony mass with reconstruction by bone grafts or joint prosthesis); or *interpositional arthroplasty* (resection of the bony mass with interposition of a biological material or non-biological material). Lindqvist (1986) recognized costochondral graft as the preferred biological material in children because it may allow additional mandibular growth. The interpositional arthroplasty with a temporalis muscle flap is advocated by Feinberg (1989), Umeda (1993) and Su-Gwan (2001).

Material & Methods:

Four patients with TMJ ankylosis were treated at the department of oral and maxillofacial surgery at People's Dental academy, Bhopal during last two years. All the cases were treated surgically under general anaesthesia using fibre-optic intubation. The procedure used was inter-positional arthroplasty of the TMJ using temporalis myofascial flap.

Pre-operative assessment included the clinical history of the patient, physical and radiographic examination. Data was collected with regards to the cause of the ankylosis, facial asymmetry, presence of

Corresponding Author: Dr K Rajanikanth, HIG-14, People's Dental Academy Campus, People's Campus Bhanpur, Bhopal 462037 (M.P.)

Phone No.: 9755029199

E mail : drrajanikanth@indiatimes.com

micrognathia, the time of onset of the ankylosis, the side affected, and the nature of the union (fibrous / bony). Measurements of maximal inter-incisal opening (Fig.I), lateral movements and protrusion were made a day before the surgical procedure. The radiographic examination included panoramic radiographs and computerized axial tomograms (Fig. II) to determine the anatomic boundaries of ankylosis and the type of ankylosis.

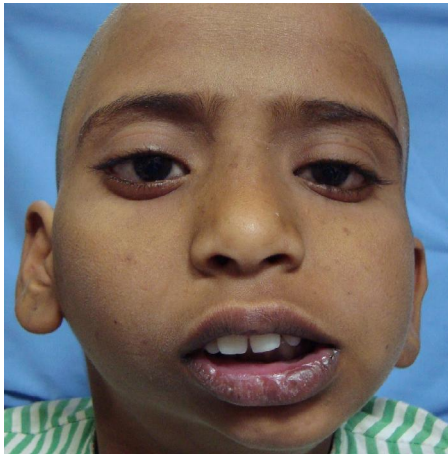

Fig. I: Photograph showing mouth opening pre-operatively in bony type of ankylosis.

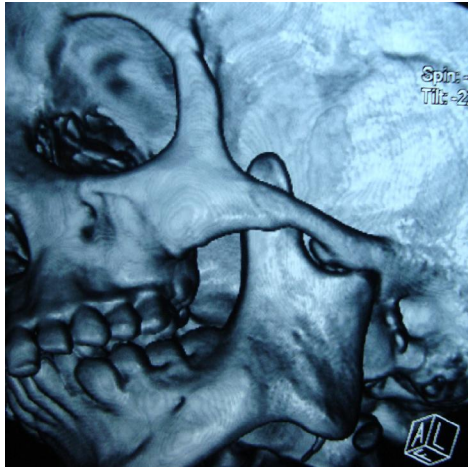

Fig. II: Photograph showing three dimensional CT reconstruction of affected TMJ.

Operative Procedure:

A written, informed and verbal consent was taken for the procedure. The temporal region was prepared. Approach to the TMJ region was gained using Al-kayat & Bramely's (1979) modified pre-auricular incision. Dissection was carried out through the superficial temporal fascia, which was retracted anteriorly to protect the facial nerve, and the periosteum over the zygomatic arch was incised. With the flap

retracted anteriorly, an incision was made through the superficial layer of temporal fascia beginning from the root of the zygomatic arch just in front of the tragus antero-posteriorly towards the upper corner of the retracted flap.

After exposing the joint and identification of the site of the ankylosis (Fig. III), aggressive excision of the fibrous and/or bony mass was done initially with drills and completed with a chisel (Fig. IV).

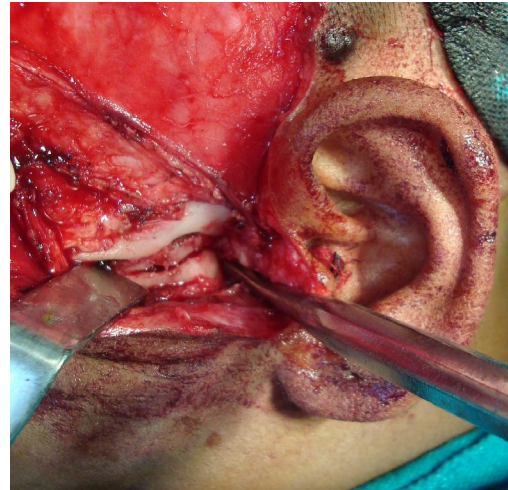


Fig. III: Photograph showing ankylosed TMJ.

Care was taken to avoid injury to the internal maxillary artery underneath the condyle. It was followed by the excision of the coronoid process and burring of the glenoid fossa creating a gap of at least 15 mm between the roof of the fossa and the mandible. A passive inter-incisal opening of at least 30 mm was achieved. Copious irrigation was done with saline. Contra lateral coronoidectomy was performed when necessary, in accordance with Kaban's protocol (1990).

A finger-shaped flap of sufficient length was marked on the temporal fascia so that after rotation it would reach the joint site easily without any undue stretching (Fig.V). The composite flap of temporal fascia and muscle was developed which would be pedicled on the branches of superficial temporal artery. The flap was rotated and sutured to the medial, anterior and posterior regions of the site of arthroplasty (Fig.VI) so that it covers the cut ends of the arthroplasty completely and effectively. Layer-wise closure was done and a surgical drain placed. The physiotherapy began after two days post-operatively with jaw exercises under supervision. It was intensified gradually in the post-operative and recall period (Fig.VII).

Results:

Four patients were subjected to TMJ surgery: one male and three females. All the females had unilateral bony ankylosis (CT findings) with minimal mouth opening. The male was having fibrous ankylosis of right TMJ with an opening of 11 mm pre-operatively.

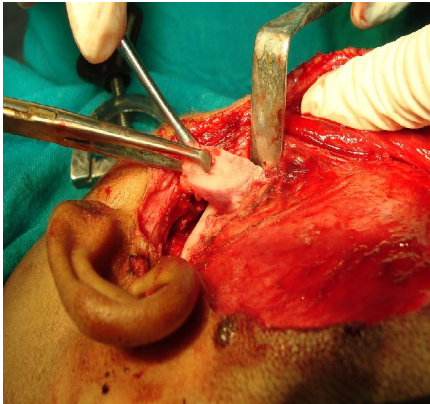


Fig.IV: Photograph showing resected ankylosed mass.

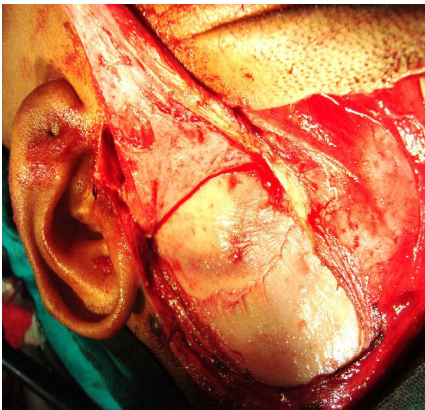


Fig.V: Photograph showing elevation of Temporalis myofascial flap.

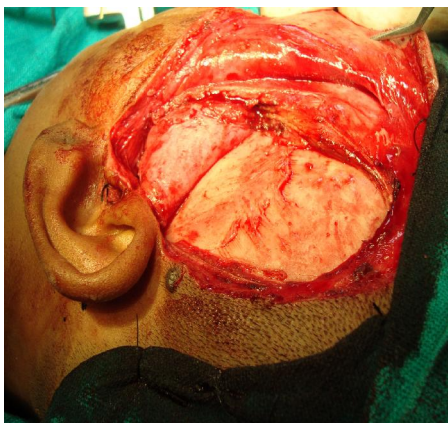


Fig.VI: Photograph showing interpositioning of the temporalis myofascial flap.

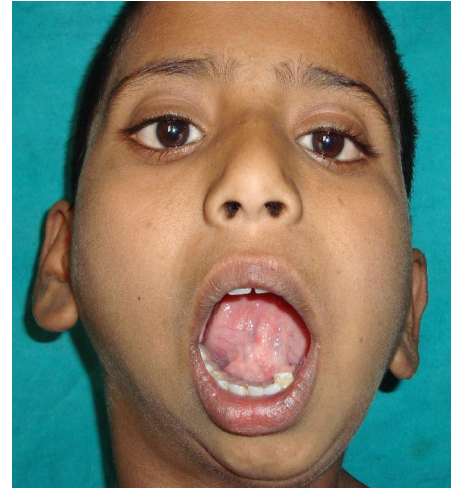


Fig.VII: Photograph showing inter-incisal post-operatively of the same patient as showing the fig. I.

The mean age was 14.25 years and aetiology included trauma in all the cases. Only one case was operated previously elsewhere and had recurrence within 1 year. Follow-up period ranged from 3 months to 2 years. The various measurements are grouped and depicted in Table 1.

Table I: Pre & Post-Operative measurements of inter incisal opening in the patients

S. No	Age/ Sex	Type of ankylosis	Pre-operative mouth opening	Post-operative mouth opening	Post-operative follow-up period
1.	14 / F	Bony	Nil	34 mm	2 years
2.	11/ M	Fibrous	11 mm	39 mm	1yr 8 months
3.	15/ F	Bony	Nil	36 mm	7 months
4.	17/ F	Bony	Nil	38 mm	3 months

Discussion:

Early ankylosis of TMJ in children can be a deterrent to normal mandibular growth. Therefore, early diagnosis of TMJ ankylosis and early surgical intervention is important. Management of TMJ ankylosis is mainly performed through surgical intervention. Various techniques for the management of TMJ ankylosis have been described. However, no single technique has proved entirely satisfactory. The characteristic pathology of ankylosis is the formation of a bony mass, which replaces the articulation, resulting in restriction of mandibular movements. For this reason, treatment of TMJ ankylosis requires removal of a sufficient amount of bone to allow for free movement of the mandibular stump and interposition of some

material between the remaining ramus and skull base. It is necessary to use an interpositional material to prevent TMJ re-ankylosis after arthroplasty (or condylectomy). This particular aspect of the treatment has been the subject of numerous discussions. The use of various allogenic interpositional materials has led to serious complications, including foreign body reaction and migration. Homografts, such as skin, temporalis muscle, or fascia lata, are considered as the material of choice for interposition.

In recent years, a pedicled temporalis myofascial or temporal fascia flap has been advocated in TMJ surgery to treat the TMJ ankylosis (Feinberg & Larsen, 1989). Advantages of these flaps in TMJ reconstruction include close proximity to the TMJ without involving an additional surgical site, adequate blood supply, autogenous origin, and maintenance of attachment to the coronoid process which provides movement of the flap during function, simulating physiologic action of the disc. Its proximity to the joint allows for a pedicled transfer of vascularized tissue into the joint area. In this case a composite (fascia, muscle, and periosteum) axial flap was harvested, as described by Herbosa & Rotskoff (1990). The axial flaps were easily rotated inferiorly into the joint space. Rotation under the zygomatic arch prevents bulkiness and avoids the need for surgically reducing the thickness of the zygomatic arch, as suggested by Pogrel & Kaban (1990), when rotating the muscle over the arch.

Regarding the fate of temporalis muscle graft, Umeda et al (1993) have demonstrated by magnetic resonance imaging that the flaps appeared to be viable and the tissue signal was compatible with vital muscle and / or fat as opposed to tissue scarring.

Bibliography:

- Al kayat A, Bramley P: A modified pre-auricular approach to the Temporo-mandibular joint and molar arch. *British Journal of Oral Surgery*, 1979; 17:91-103.
- Feinberg SE, Larsen PE: The use of a pedicled temporalis muscle-pericranial flap for replacement of the TMJ disc: preliminary report. *Journal of Oral and Maxillofacial Surgery*, 1989; 47: 142-146.
- Herbosa EG, Rotskoff KS: Composite temporalis pedicle flap as an interpositional graft in temporomandibular joint arthroplasty: a preliminary report. *Journal of Oral and Maxillofacial Surgery*, 1990; 48(11): 1049-1056.
- Kaban LB, Perrott DH, Fisher K, Topazian RG: A Protocol for Management of Temporo-mandibular Joint Ankylosis. *Journal of Oral and Maxillofacial Surgery*, 1990; 48(11):1145-1151.
- Kazanjian VH: Temporo-mandibular ankylosis with mandibular retrusion. *American Journal of Surgery*, 1955;90: 905-910.
- Laskin DM: Role of the meniscus in the etiology of post traumatic temporomandibular joint ankylosis. *International Journal of Oral Surgery*, 1978;7(4):340-345.
- Lindqvist C, Pihakari A, Tasanen A, Hampf G: Autogenous costochondral grafts in TMJ arthroplasty. A survey of 66 arthroplasties in 60 patients. *Journal of Maxillofacial Surgery*, 1986; 14(3):143-149.
- Pogrel MA, Kaban LB: The role of a temporalis fascia and muscle flap in temporomandibular joint surgery. *Journal of Oral and Maxillofacial Surgery*, 1990; 48 (1):14-19.
- Smith JA, Sandler NA, Ozaki WH, Braun TW: Subjective and objective assessment of the temporal myofascial flap in previously operated temporomandibular joints. *Journal of Oral and Maxillofacial Surgery*, 1999; 57(9):1058-1065.
- Su-Gwan K: Treatment of temporomandibular joint ankylosis with temporalis muscle and fascia flap. *International Journal of Oral and Maxillofacial Surgery*, 2001;30(3):189-193.
- Umeda H, Kaban LB, Pogrel MA, Stren M, Rotskoff KS: Long-term viability of temporalis muscle/fascia flap used for temporomandibular reconstruction. *Journal of Oral and Maxillofacial Surgery*, 1993;51(5):530-534.