Research Article

Anatomical Variations in Formation and Branching Pattern of the Femoral Nerve in Iliac Fossa: A Study in 64 Human Lumbar Plexuses

Rajesh B Astik, Urvi H Dave

Department of Anatomy, GSL Medical College, Rajahmundry - 533296

Abstract:

Femoral nerve is used for nerve block in several surgeries and is vulnerable to compression in tight ilio-psoas compartment. The knowledge of origin and variations of femoral nerve in iliac fossa is important for anatomists, anesthetists and surgeons to prevent iatrogenic femoral nerve palsy.

We dissected 32 human cadavers to study the anatomy of the femoral nerve. We dissected the lumbar plexus bilaterally; dissected the psoas major muscle to see formation of the femoral nerve. We measured the length of the femoral nerve from its formation to inguinal ligament; and recorded variations of the femoral nerve with digital photography.

The average length of the femoral nerve was 144 mm. Anatomical variations of the femoral nerve were found in 25% lumbar plexuses. These variations included abnormally long L2 root, early division of the femoral nerve, origin of lateral cutaneous nerve of thigh from the femoral nerve, origin of nerve to pectineus from the femoral nerve in iliac fossa, splitting of the femoral nerve into two slips by psoas major or accessory slips of iliacus muscle.

The aim of this study was to highlight variations in branching pattern of the femoral nerve in iliac fossa for appropriate exposure of the femoral nerve.

Key Words: Anatomical variations, Femoral nerve, Iliacus muscle, Nerve block, Psoas major muscle.

Introduction:

The femoral nerve is the largest branch of the lumbar plexus. It arises from the dorsal branches of second to fourth ventral rami. Conventionally the femoral nerve passes behind the inguinal ligament and divides into anterior and posterior divisions in the thigh (Newell, 2005). The femoral nerve block is performed on the main trunk of the femoral nerve just below the inguinal ligament (Ellis et al, 2004). The higher division of the femoral nerve in iliac fossa results in incomplete femoral nerve block.

Variant origin of the femoral nerve branches has wide clinical relevance. Nerve to pectineus arises from medial aspect of the femoral nerve near the inguinal ligament, passes behind the femoral sheath and enters the anterior aspect of the muscle (Newell, 2005). Origin of nerve to pectineus from the femoral nerve in iliac fossa and absence of nerve supply to pectineus either from obturator nerve or accessory obturator nerve is more important morphologically than clinically. Origin of lateral cutaneous nerve of thigh from the femoral nerve may confuse the practitioner in treatment of meralgia paraesthetica.

Aberrant slip of iliacus or psoas major muscle sometimes splits the femoral nerve (Spratt et al, 1996; Vazquez et al, 2007; Anloague & Huijbregts, 2009). The detailed knowledge of the possible variations of these muscles and femoral nerve may have immense importance in various pelvic and pelvi-femoral surgeries.

The objective of this study was to dissect, identify and document variations in the anatomy of the femoral nerve and its branching pattern in iliac fossa. This knowledge could then be used to validate previously described anatomy of ilio-psoas compartment and various surgical approaches to expose the femoral nerve.

Materials & Methods:

Variations in branching pattern of the femoral nerve in thigh have been widely reported in literatures. Variation of origin and branching pattern of the femoral nerve in iliac fossa has wide clinical implications.

The femoral nerve was studied during routine educational dissection of 32 human cadavers of Asian origin in the department of anatomy over a period of three years. There were 24 male and 8 female cadavers with mean age of 48 years. There were no signs of trauma, surgery or wound scars in the abdominal regions of any of the cadavers.

The skin, superficial fascia, muscles of anterior abdominal wall and all abdominal viscera were removed to expose the posterior abdominal wall. The exposure of origin of femoral nerve was done by removing psoas

Corresponding Author: Dr. Rajesh B. Astik, Associate Professor, Depatment of Anatomy, GSL Medical College, NH-5, Laxmipuram, Near Rajanagaram, Rajahmundry-533296 (A.P.)
Phone No.: +91 - 9885047241, 883-2484999
E-mail : astikrajesh@yahoo.co.in

major muscle piece by piece.

The lengths of the L2, L3 and L4 roots from corresponding intervertebral foramen to the formation of the femoral nerve, and length of the femoral nerve from its formation to the point where it passed deep to the inguinal ligament was measured with a thread which was measured with a scale (Table I). The epineurium of the L2, L3, L4 roots, of the femoral nerve and of the nerve to pectineus were opened to find the contribution of femoral nerve, obturator nerve or accessory obturator nerve, if present, to supply the pectineus muscle; we traced the fascicles in nerve to pectineus back into trunk of the femoral nerve.

The variations in the formation and branching pattern of the femoral nerve were recorded; and it's varied relationship to the ilio-psoas complex, if any, was photographed and documented.

Since the hip joints were disarticulated before the dissection of lumbar plexuses, so we did not study the branching pattern of the femoral nerve in the thigh.

Results:

After careful dissection of the psoas major muscle, we exposed L2, L3 and L4 roots of the femoral nerve. We measured the lengths of L2, L3, L4 roots, and of the femoral nerve.

We found that lengths of roots of femoral nerve reduced from L2 to L4. Abnormally long L2 root (92 mm in a cadaver) resulted in very short course of femoral nerve (35 mm) in the iliac fossa (Table I).

Table I: Showing length of lumbar roots and of the femoral nerve.

Roots and FN	Length landmarks		Mean length (range) mm
	From	To	
L2	IVF between L2 & L3	Formation of FN	34 (28-92)
L3	IVF between L3 & L4	Formation of FN	20 (18-25)
L4	IVF between L4 & L5	Formation of FN	18 (15-20)
FN	Formation of FN	The point where FN passes below IL	144 (35-149)

Femoral nerve (FN), intervertebral foramen (IVF), inguinal (IL) ligament

We recorded anatomical variations such as abnormally long L2 root, early division of the femoral nerve, origin of lateral cutaneous nerve of thigh directly from the femoral nerve, origin of nerve to pectineus in iliac fossa and splitting of the femoral nerve by psoas major or accessory slip of iliacus muscle with digital photography. We noted the variations in the formation and branching pattern of the femoral nerve; and its varied relationship to the ilio-psoas complex in 16 of the 64 (25%) of the lumbar plexuses dissected.

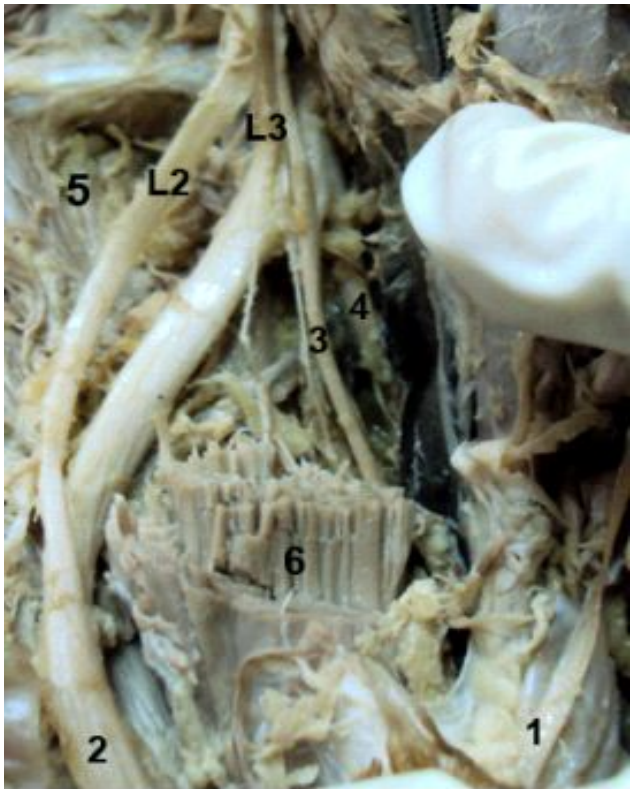

Fig. I Abnormally long L2 root fused with combined L3 & L4 roots 35 mm above the inguinal ligament. 1 inguinal ligament cut, 2 femoral nerve, 3 obturator nerve, 4 lumbosacral trunk, 5 iliacus, 6 psoas major

We found abnormally long L2 root on both sides in a male cadaver. On the right side, it was 92 mm long. After emerging from intervertebral foramen between L2 and L3 vertebrae, it divided into ventral and dorsal divisions. The ventral division fused with ventral divisions of L3 and L4 roots to form obturator nerve; and the dorsal division of L2 descended in iliac fossa and fused with combined dorsal divisions of L3 and L4 to form the femoral nerve 35 mm above the inguinal ligament (Fig.I). On the left side L2 root was 85 mm long, had the same course as on the right side, and it fused with combined dorsal divisions of L3 and L4 to form the femoral nerve 42 mm above the inguinal ligament.

We found early division of the femoral nerve in two lumbar plexuses. In a right lumbar plexus of a male cadaver, the femoral nerve divided in iliac fossa 40 mm above the inguinal ligament into anterior and

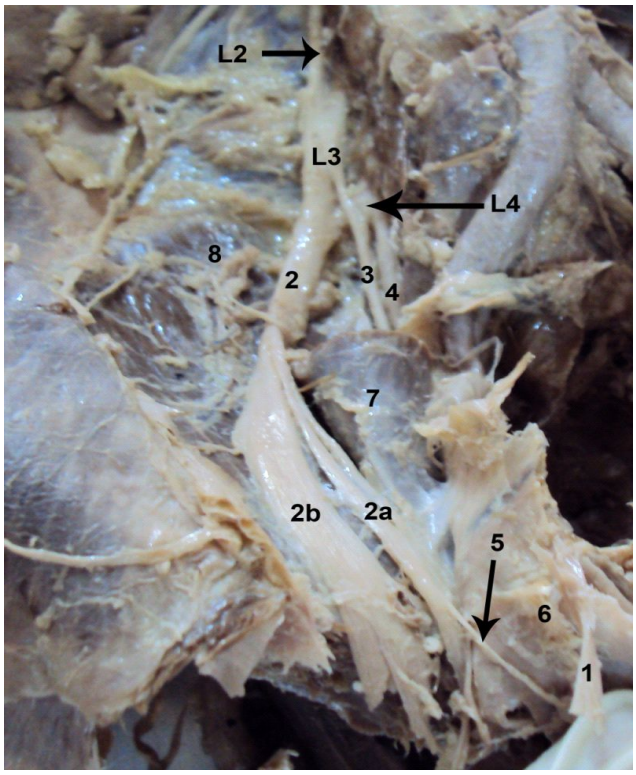

Fig.II: Early division of the right femoral nerve in iliac fossa. Nerve to pectineus arising from anterior division behind the inguinal ligament. 1 inguinal ligament cut, 2 femoral nerve, 2a anterior division of femoral nerve, 2b posterior division of femoral nerve, 3 obturator nerve, 4 lumbosacral trunk, 5 nerve to pectineus, 6 pectineus, 7 psoas major cut, 8 iliacus.



Fig.III: Right lateral cutaneous nerve of thigh arising from the femoral nerve. 1 lateral cutaneous nerve of thigh, 2 femoral nerve, 3 obturator nerve, 4 nerve to psoas major, 5 iliacus, 6 nerve to iliacus

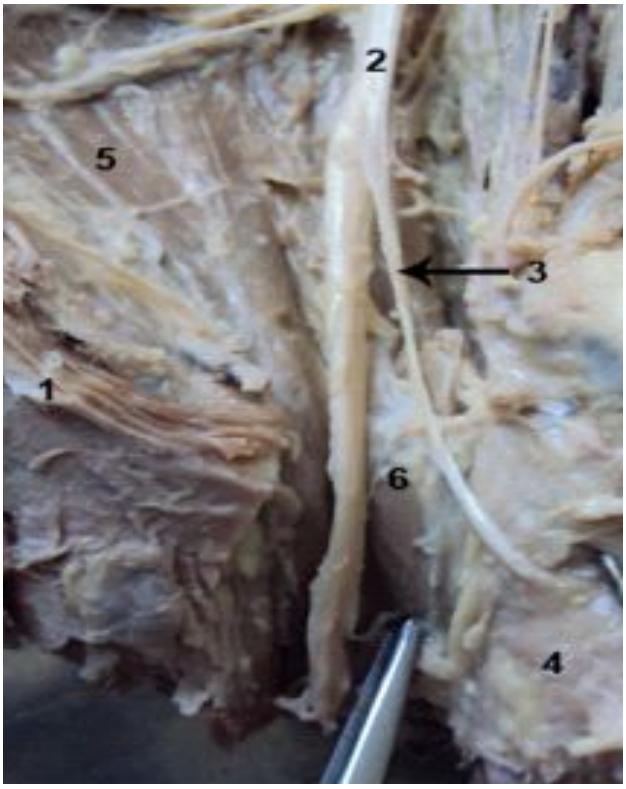

Fig.IV: Nerve to pectineus arising from the femoral nerve in right iliac fossa 45 mm above the inguinal ligament. 1 inguinal ligament, 2 femoral nerve, 3 nerve to pectineus, 4 pectineus, 5 iliacus, 6 psoas major.

posterior divisions. The nerve to pectineus arose from the anterior division of the femoral nerve (Fig. II). In a female cadaver, the left femoral nerve divided in the iliac fossa 38 mm above the inguinal ligament.

The lateral cutaneous nerve of thigh is normally a branch of the lumbar plexus. We found the origin of lateral cutaneous nerve of thigh from the femoral nerve in four lumbar plexuses (Fig. III).

Normally, nerve to pectineus arises from the femoral nerve below the inguinal ligament. We found the origin of the nerve to pectineus from the femoral nerve in iliac fossa in three lumbar plexuses. In one plexus, it arose 45 mm above the inguinal ligament in a male cadaver (Fig. IV); and in other male cadaver, it was a branch of anterior division of the right femoral nerve, which arose 25 mm above the inguinal ligament (Fig. II). We found all the fascicles of nerve to pectineus in the trunk of femoral nerve. In all the three lumbar plexuses neither obturator nor accessory obturator were supplying the pectineus.

We found splitting of the femoral nerve by psoas major muscle into larger medial and smaller lateral slips in three lumbar plexuses, the lateral slip fused with the medial slip to form main trunk of the

Fig.V: Left psoas major muscle splits femoral nerve. *1* femoral nerve, *2* obturator nerve, *3* psoas major, *4* iliacus

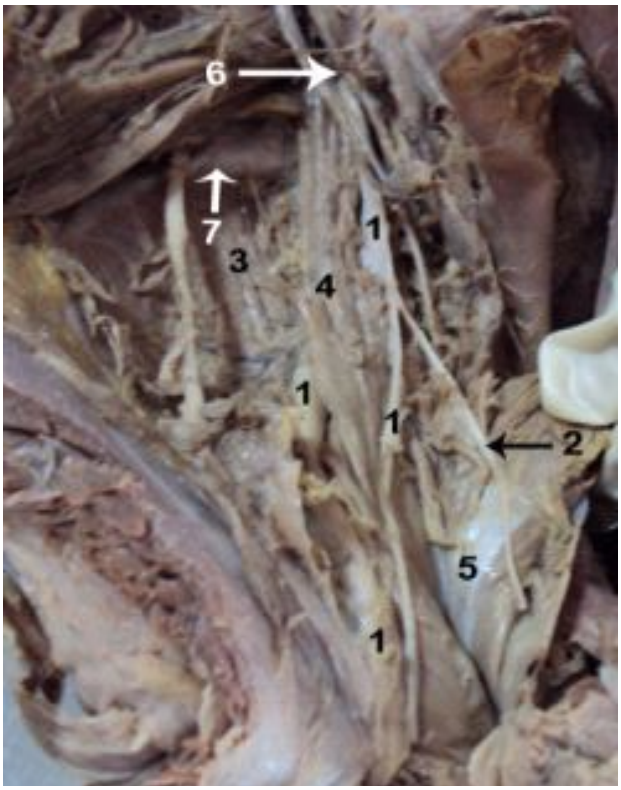

Fig.VI: Accessory slip of iliacus muscle splits the femoral nerve on right side. *1* femoral nerve, *2* nerve to psoas major arising from femoral nerve, *3* iliacus, *4* accessory slip of iliacus, *5* psoas major, *6* fifth lumbar transverse process and ilio-lumbar ligament, *7* iliac crest

femoral nerve 45 mm above the inguinal ligament in two plexuses and 40 mm above the inguinal ligament in one plexus (Fig. V). Further course and branching pattern of the femoral nerve were found to be normal. In all the three lumbar plexuses, neither obturator nerve nor accessory obturator nerve were supplying the pectineus muscle.

We found origin of accessory slip of the iliacus muscle from the transverse process of the fifth lumbar vertebra and iliolumbar ligament on the right side, connected with iliacus muscle by few muscle fibers, splitting the femoral nerve into two slips, in two lumbar plexuses (Fig. VI).

We did not find any significant sexual difference or lateralization in the formation and variation in branching pattern of the femoral nerve in iliac fossa.

Discussion:

The femoral nerve, the psoas major and iliacus muscles roofed over by the iliac~~us~~ fascia, form a tight fascial compartment, which accounts for femoral nerve lesions due to space-occupying processes in this area. In the cases of femoral nerve paralysis, neuropathy caused by iliac hematoma after anticoagulant treatment (Galzio et al, 1983) or vessel catheterization (Warfel et al, 1993), the existence of some variant muscles or variations in branching pattern of the femoral nerve may increase the chances of nerve compression.

To the best of our knowledge, abnormally long L2 root is not documented in literatures. We found abnormally long L2 root bilaterally in a male cadaver and knowledge of this variation in the formation of the femoral nerve may be important to anesthetists for successful lumbar plexus block.

Femoral nerve divided 3.2 cm above the mid-inguinal point in a male cadaver on both sides (Das &Vasudeva, 2007). We found division of femoral nerve in two plexuses at variable distance above the mid-inguinal point. Schultz et al (1991) has reported that lumbar plexus blockade have a lower incidence of complications than epidural blockade. The knowledge of early division of femoral nerve in iliac fossa is required to avoid incomplete femoral nerve block.

Lateral cutaneous nerve of thigh arose directly from the femoral nerve in 6 (10%) plexuses (Sim & Webb, 2004). Dias Filho et al (2003) reported origin of lateral cutaneous nerve of thigh from the femoral nerve inferior to the inguinal ligament in one case in their study. Uzmansel et al (2006) reported origin of accessory lateral cutaneous nerve of thigh from the

femoral nerve above the inguinal ligament in their case report. We found origin of lateral cutaneous nerve of thigh from the femoral nerve above the inguinal ligament in 4 plexuses. Origin of lateral cutaneous nerve of thigh from the femoral nerve may have impact on the clinical efficacy of lumbar plexus blockade, since femoral nerve blockade is likely to produce blockade in the area of distribution of lateral cutaneous nerve of thigh in these plexuses. Similarly, lateral cutaneous nerve of thigh blocks would produce femoral nerve blockade as described by Sharrock (1980). The impact of the presence of this variation on femoral and lateral cutaneous nerve of thigh blockade is yet to be investigated.

Femoral nerve supplies dorsal larger part of the pectineus muscle by one or two branches, arising in thigh, and ventral smaller part is supplied either by obturator nerve or accessory obturator nerve. One of the two branches from the femoral nerve may be given off in the abdomen (Paterson, 1891). Macalister (1889) described origin of nerve to pectineus from the femoral nerve within the abdomen with the medial cutaneous nerve of thigh. We found nerve to pectineus arose from the femoral nerve within the abdomen in three plexuses. In two plexuses, nerve to pectineus arose from the main trunk of the femoral nerve and in one plexus it arose from the anterior division of the femoral nerve. We found fascicles from ventral divisions of L2, L3 and L4 roots passing through the femoral nerve and supplying the pectineus muscle. In such cases the nerve to pectineus should be named as accessory femoral nerve.In all the three lumbar plexuses, neither obturator nerve nor accessory obturator nerve gave branches to the pectineus muscle..

Variant slips of the iliacus and psoas major muscles split the femoral nerve into two or three separate slips in 35.3% (Anloague & Huijbregts, 2009), 7% (Vazquez et al, 2007) and 2.2% (Spratt et al, 1996). Jakubowicz (1991) reported splitting of the femoral nerve by lateral fibers of psoas major muscle in 2.5% and by muscle fibers of iliacus in 2.5% in fetal lumbar plexus. Jelev et al (2005) reported accessory iliopsoas muscle splitting the left femoral nerve in a female cadaver. We found splitting of the femoral nerve into two slips by muscular slip of psoas major in three plexuses and by accessory iliacus slip in two plexuses. The femoral nerve slips fused with each other at variable distance above the inguinal ligament. Variant muscular slip of psoas major or accessory slips from iliacus which cause tension of the femoral nerve and, therefore, should be suspected in patients with referred pain to the hip and knee joints (Spratt et al, 1996). The accessory muscles may be seen as interesting findings in patients during retroperitoneal surgery in the lower lumbar region and should be kept in mind in the differential diagnosis on CT imaging of the iliopsoas compartment (Lenchik et al, 1994).

The anatomical variations of the femoral nerve can be explained on the embryological basis. Limbs develop in the form of buds of cellular undifferentiated mesoblast before the spinal nerves have any connection with them. Somatic branches of the nerves then stream out into the limb bud, passing into it below the ends of the myotomes and spreading out into a bundle of fibers at the proximal attachment of the limb. Later on, the nerves separate each into a pair of definite trunks, which are named dorsal and ventral, dividing round a central core of mesoblast and proceed to the dorsal and ventral surfaces of the limb bud respectively. While this process is going on, a secondary union takes place between parts of adjacent dorsal and ventral trunks. Dorsal trunks unite with other dorsal trunks, whereas the ventral trunks unite with ventral trunks, to form the nerves distributed ultimately to the surfaces and periphery of the limb (Cunningham, 1905). Variations in formation and branching pattern of the femoral nerve may occur due to abnormal union of dorsal and ventral trunks of the nerve during the fourth week of intrauterine development. These anatomical variations are usually concomitant with compensatory variations in adjacent nerves, and are due to the fibers of a given spinal nerve taking an abnormal course in the trunk of another nerve of distribution and effecting a communication with the proper nerve peripherally (Cunningham, 1905). In this way variations in the origin and distribution of nerve to pectineus from the femoral nerve and origin of lateral cutaneous nerve of thigh from the femoral nerve, and splitting of the femoral nerve by psoas major or accessory iliac muscle may be explained.

The knowledge of anatomical variations of the femoral nerve is essential for the surgeons to avoid iatrogenic injury to the femoral nerve, for the clinicians who are treating patients with meralgia paresthetica as lateral cutaneous nerve of thigh may arise from the femoral nerve, for the anesthetists to give successful block in femoral or lateral cutaneous nerve of thigh and for the anatomists to understand morphological importance of origin of nerve to pectineus in the abdomen.

Acknowledgements

Our sincere thanks to all the people who helped and supported during the writing of this manuscript. We would thank our institution for allowing us to dissect cadaver and faculty members without whom this manuscript would have been a distant reality.

Bibliography:

1. Anloague PA, Huijbregts P: Anatomical Variations of the Lumbar Plexus: A Descriptive Anatomy Study with Proposed Clinical Implications. *The Journal of Manual & Manipulative Therapy*, 2009; 17(4): e107-e114.
2. Cunningham DJ: Text book of Anatomy. 2nd Edn.; William Wood and Company, New York, 1905; pp. 662- 673.
3. Das S, Vasudeva N: Anomalous higher branching pattern of the femoral nerve: a case report with clinical implications. *Acta Medica (Hradec Kralove)*, 2007; 50 (4): 245–246.
4. Dias Filho LC, Valenc MM, Guimaraes FA, Medeiros RC, Silva RA, Morais MG, Valente FP, Franca SM: Lateral femoral cutaneous neuralgia: an anatomical insight. *Clinical Anatomy*, 2003; 16 (4): 309–316.
5. Ellis H, Feldman SA, Harrop Griffith W: Anatomy for anaesthetists. 8th Edn.; Blackwell publishing, Massachusetts, 2004; pp. 188–191.
6. Galzio R, Lucantoni D, Zenobii M, Cristuib-Grizzi L, Gadaleta A, Caffagni E: Femoral neuropathy caused by iliacus hematoma. *Surgical Neurology*, 1983; 20 (3): 254-257.
7. Jakubowicz M: Topography of the femoral nerve in relation to components of the ilio-psoas muscle in human fetuses. *Folia Morphologiica*, 1991; 50 (1-2): 91–101.
8. Jelev L, Shivarov V, Surchev L: Bilateral variations of the psoas major and the iliacus muscles and presence of an undescribed variant muscle-accessory iliopsoas muscle. *Annals of Anatomy*, 2005; 187 (3): 281–286.
9. Lenchik L, Dovgan DJ, Kier R: CT of the iliopsoas compartment: value in differentiating tumor, abscess and hematoma. *American Journal of Roentgenology*, 1994; 162(11): 83–86.
10. Macalister A: Text-book of Human Anatomy. 1889: pp. 467-490.
11. Newell RLM: Pelvic girdel, gluteal region & hip joint . In: Gray's anatomy - The anatomical basis of clinical practice. S Satanding, H Ellis, JC Healy, D Jhonson, A Williams, Eds.; 39th Edn.; Elsevier Churchill Livingstone, Philadelphia, 2005; p.1455.
12. Paterson AM: The Pectineus and its Nerve Supply. *Journal of Anatomy and Physiology*, 1891; 26 (Pt 1): 43-47.
13. Schultz P, Anker-Moller E, Dahl JB, Christensen EF, Spangsberg N, Fauno P: Postoperative pain treatment after open knee surgery: Continuous lumbar plexus block with bupivacaine versus epidural morphine. *Regional Anesthesia*, 1991; 16 (1): 34-37.
14. Sharrock N: Inadvertent "3-in-1" block following injection of the lateral cutaneous nerve of thigh. *Anesthesia and Analgesia*, 1980; 59 (11): 887-888.
15. Sim IW, Webb T: Anatomy and anaesthesia of the lumbar somatic plexus. *Anaesthesia and Intensive Care*, 2004; 32 (2): 178-187.
16. Spratt JD, Logan BM, Abrahams PH: Variant slips of psoas and iliacus muscles, with split-ting of the femoral nerve. *Clinical Anatomy*, 1996; 9 (6): 401–404.
17. Uzmansel D, Aktekin M, Kara A: Multiple variations of the nerves arising from the lumbar plexus. *Neuroanatomy*, 2006; 5 (1): 37–39.
18. Vazquez MT, Murillo J, Maranillo E, Parkin IG, Sanudo J: Femoral nerve entrapment: A new insight. *Clinical Anatomy*, 2007; 20 (2): 175-179.
19. Warfel BS, Marini SG, Lachmann EA, Nagler W: Delayed femoral nerve palsy following femoral vessel catheterization. *Archives of Physical Medicine and Rehabilitation*, 1993; 74 (11): 1211–1215.