

Aluminium Induced Microscopic Changes in the Kidney

Shilpi Jain, Satyam Khare, *Archana Sharma, Virendra Budhiraja, Rakhi Rastogi

Department of Anatomy, Subharti Institute of Medical Sciences, Meerut-250002, *Muzaffarnagar Medical College, Muzaffar Nagar-251001(U.P.)

Abstract:

Reports of aluminium toxicity on kidneys through dietary source is less reported even though it's adverse effects such as encephalopathy, dementia, osteomalacia and fractures have been reported in renal failure cases after ingestion of aluminium gel. As Majority of Indian population is exposed to aluminium through dietary source, therefore, the effects of aluminium toxicity was studied in albino rats after oral administration of Aluminium salts.

The present study was carried out on 40 albino rats divided into two equal group: control and experimental. Each of twenty animals of experimental group were given 37.5 mg of aluminium chloride per day orally for 3 weeks. All the animals were sacrificed on 22nd day. Small pieces of kidney were procured, fixed in 10% neutral buffered formaline and embedded in paraffin. Sections of 7 μ thickness were cut and stained with Haematoxylin and Eosin for general morphology and PAS for basement membrane. Significant histopathological changes were observed. Breakdown of general architectural pattern with degenerative changes were seen more in cortex as compared to medulla. Haemorrhage and inflammatory cell reaction was also observed in cortex.

Key Words: Aluminium, Toxicity, Histopathology, Kidney.

Introduction:

Aluminium is the most abundantly available metal in the crust of earth. It's production and use are enormous as compared to any other heavy metal. It is extensively used in building, canning, tanning, automobile, aviation, paint, paper, ceramic and glassware industries. Annual production of aluminium is about 22,000 metric tones worldwide (Neelam et al, 1999). It is a metal of choice in making different kinds of cookware and storage utensils. 10-15% production of aluminium compounds are utilized in processing, packaging and preservation of food such as aluminum foils etc. Formerly, aluminium and its salts were believed to be non toxic so it's use in medicine increased substantially. Aluminium magnesium silicate and aluminium hydroxide are used as antacid and aluminium gel as phosphate binding agent to lower plasma phosphorous level in patients suffering from acute renal failure. Aluminium intake in such patients is approximately between 800 to 5000 mg/day (Alfrey, 1983) which is far beyond the provisional tolerable weekly intake of aluminium (PTWI). According to WHO, PTWI of aluminium as a contaminant is 7 mg/kg body weight for adults, where as acceptable daily intake (ADI) for children is 2mg./kg body weight

(WHO series, 1989). Aluminium as a potential occupational toxin is known for almost five decades. Chronic inhalation of extremely fine dust of aluminium compounds by human causes toxic pulmonary reaction called Shaver's Disease (Shaver & Riddell, 1947) and inhalation of the fine particles of aluminium metal dust in factories cause both encephalopathy and pulmonary fibrosis in human beings. Aluminium has also been implicated in neurotoxicity associated with amyotrophic lateral sclerosis (Garruto et al, 1984) and Alzheimer's disease (Perl, 1985) in indigenous population of Guam where soil have aluminum as high as 150-600 gm/kg (Sorenson et al, 1974). One of the main exposure of aluminium is through diet in addition to environment and occupation. Because of the wide use of aluminium cookware and storage vessels, the intake of aluminium by Indian population is much higher than what has been reported for the West. One of the main organ affected by aluminium ingestion is kidney (Smith, 1982; Chagnac et al, 1987). The present study was conducted to find out the histopathological changes in kidneys after administration of aluminium through oral route.

Material and Methods:

Forty Albino rats of both sexes weighing approximately 120 gms each were used for the present study. The animals were housed in a well lighted &

Corresponding Author: Dr. Shilpi Jain, Associate Professor, Department of Anatomy, Subharti Institute of Medical Sciences, Delhi - Haridwar Bypass Road, Meerut-250002 (U.P.)
Phone No. 9927009518, 0121-2439056

ventilated room. No artificial light was used. Food consisting of chapati (60 gm) and chana (20 gm) and water *ad libitum* were given. The animals were divided into two groups as control and experimental comprising of 20 animals each. Three hundred & Seventy five mg of aluminium chloride was dissolved in 10 ml of distilled water. 1ml/day of this solution was administered intra gastrically with the help of a cannula in experimental animals. Animals belonging to control group were given equal amount of distilled water intra gastrically. All the animals of both the group were sacrificed after twenty one days by stroking the dorsal aspect of body (Ghosh, 1984).

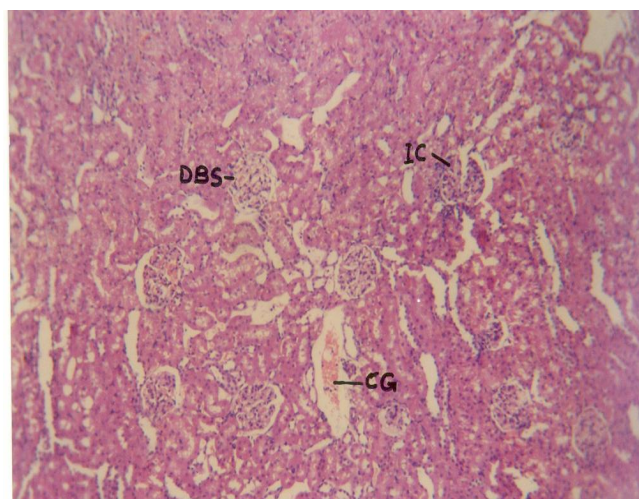


Fig. I: Photomicrograph of Kidney showing congestion-CG, Increased Cellularity- IC & Decreased Bowman's space-DBS (H & E, X 100).

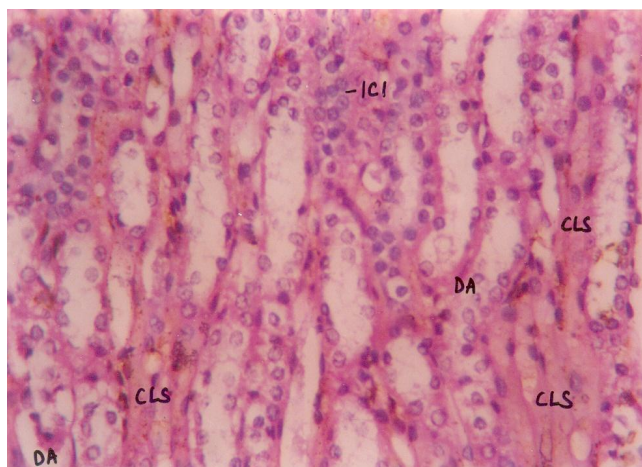


Fig. II: Photomicrograph of renal tubules showing Inflammatory Cell Infiltration-ICI, Derangement of Architecture-DA & Cloudy swelling-CLS (H & E, X 400)

Thereafter, the animals were perfused with 10% buffered formaline. The small pieces of kidney tissues were procured and preserved in 10% neutral buffered

formaline. The tissue was subjected to further histological processing. Seven micron thick paraffin sections were cut and stained with haematoxyline and eosine for demonstration of general morphology and some section were stained with PAS stain for demonstration of basement membrane.

Observations:

Thirty fields were examined per slide and the histological changes were divided into mild, moderate and severe according to the findings. Changes in less than ten field were considered as mild, in ten to twenty fields as moderate & changes in more than twenty fields were considered as severe.

Various grades of cloudy swelling of tubules, obliterated bowman's space, increased cellularity of glomeruli, inflammatory cell infiltration and partial sclerosis of glomeruli were seen in experimental group. In contrast 70% animals of control group showed only congestion (Table, 1)

Table 1: Showing histopathological changes in kidney (30 fields/slide)

Finding	Control Group (20 Animals)	Experimental Group (20 Animals)		
		Mild Changes (<10 fields)	Moderate Changes (10-20 fields)	Severe Changes (>20 fields)
Cloudy swelling in tubules	-	20%	30%	50%
Congestion	70%	-	25%	75%
Obliterated bowman's space	-	50%	30%	20%
Increased cellularity in some glomeruli	-	30%	35%	35%
Inflammatory cell infiltration	-	25%	50%	25%
Partial sclerosis in some glomeruli.	-	50%	30%	20%

Discussion:

Varied histopathological changes have been observed in kidney tissue in the present study. A general architectural derangement, including degenerative changes have been observed in kidney tissue.

Somova et al (1997) observed well marked dose dependant morphological changes in kidney. They administered aluminum chloride in a dose of 20 mg./kg of body weight/ day in drinking water to rats for six months. The changes were mainly seen in the proximal tubules. The individual cell of the tubules looked swollen, tubular dilatation along with atrophy

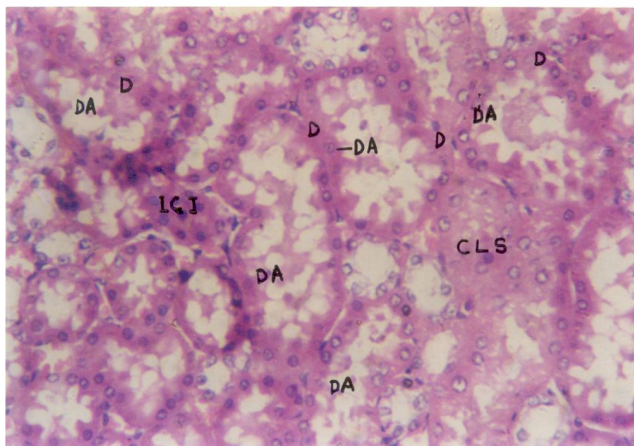


Fig. III: Photomicrograph of Kidney showing Degeneration-D, Derangement of architecture-DA, Inflammatory Cell Infiltration-ICI and Cloudy swelling-CLS (H & E X 400)

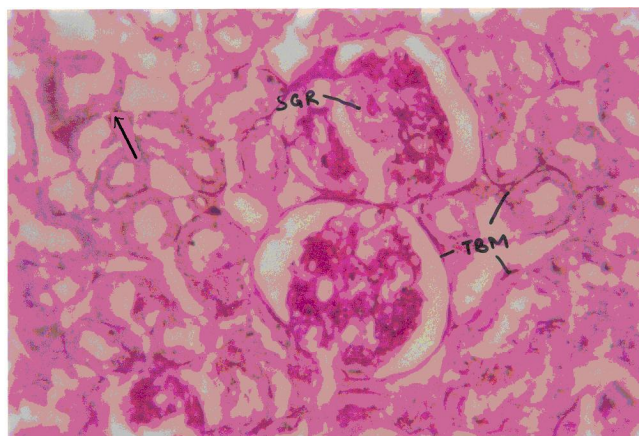

Fig. IV: Photomicrograph of Kidney showing Thickened Basement Membrane-TBM & Sclerosis of Glomeruli-SGR (P.A.S, X 400).

and loss of microvilli was seen. They also observed interstitial fibrosis around the damaged tubules and focal mesangial hypercellularity along with partial sclerosis in the glomeruli.

The above mentioned findings are in agreement with the histopathological changes observed in the present study. In addition to above findings inflammatory cell infiltration and decreased Bowman's space at places was observed in the present study.

Chagnac et al (1987) studied the renal structure of rat after long term aluminium administration. They injected aluminium chloride intraperitoneally in the doses of 0.2 mg/day and 2mg/day for 13 weeks. They did not observe any change on light microscope while electron microscopic examination showed changes in proximal tubules with increased size and number of lysosomes, vacuolisation of organelles and mitochondrial damage of varying degree. As compared to Chagnac et al (1987),

in the present study the dose administered was quite high and was given through oral route and therefore, we found changes even under light microscopic examination.

It appears that the toxokinetics are dose related and protein binding of aluminum is a significant factor. It is possible that different aluminum compounds may be giving different aluminum binding leading to differences in the biochemical lesions. The toxicity varies both in biochemical parameters as well as histological changes.

Braunlich et al (1986) reported that increased sodium excretion and paramino hippurate are the indicators of renal function injury. Smith (1982) identified aluminium containing dense deposits in glomerular basement membrane of renal tissue derived from an arthritic patient with renal failure. Henry et al (1984) reported that the parenteral administration of aluminium to dogs was associated with the rapid onset of renal function deterioration.

Ebina et al (1984) observed the findings compatible with acute tubular necrosis in rats treated with aluminium nitritotriacetic acid compound. They found severe renal damage with proximal tubular necrosis and granular cast in the distal portion of tubules. In the present study also proximal tubular degeneration was observed.

Spencer et al (1995) has measured aluminium levels in plasma and urine by atomic absorption spectroscopy and aluminium levels were also measured in kidney at cellular and subcellular levels by electron probe X-ray microanalysis (EPXMA). These authors have found significant amount of aluminium in cytoplasm and mitochondria in proximal convoluted tubules of kidney whereas raised levels were not detected in the control animals. This is indicative of concentration of aluminium in cellular organelles leading to structural and biochemical changes at subcellular level.

It is possible that the architectural derangement of kidney cells observed in the present study may be due to altered cellular organelles like mitochondria, endoplasmic reticulum, lysosomes and cell membrane by aluminium.

Conclusion:

Degenerative changes like cloudy swelling, inflammatory cell infiltration, decreased bowman's space and increased cellularity of the glomeruli have been observed in kidney of albino rats in this work

after administration of aluminium chloride orally for 21 days. The changes were more prominent in the proximal convoluted tubules of the kidney. A number of earlier observers have found that the aluminium brings about alteration at cellular and subcellular level. This is fully in agreement with the findings of this experiment.

Bibliography:

1. Alfrey A.C: Aluminium. *Advance in Clinical Chemistry*, 1983;23:69-91.
2. Braunlich H, Fleck Ch, Kersten L, Stein G, Laske V, Muller A, Keil E: Renal effects of aluminum in uraemic rats and in rats with intact kidney function. *Journal of Applied Toxicology*, 1986; 6(1):55-59.
3. Braunlich H, Penzold K, Tiersch W, Fleck C, Winnefield K, Stein G: Pharmacokinetic pattern and renal effects of aluminium in rats with impaired liver or kidney function. *Trace Element in Medicine*, 1988; 5(1):38-42.
4. Chagnac A, Ben-Bassat M, Weinstein T, Levi J: Effect of long term Aluminium Administration of Renal Structure of Rats. *Nephron*, 1987; 47(1):66-69.
5. Ebina Y, Okade S, Hamazaki S, Midorikowa O: Liver, Kidney and Central nervous system toxicity of aluminium given intraperitoneally to rats: A multiple-dose subchronic study using aluminium nitritotriacetate. *Toxicology & Applied Pharmacology*, 1984;75(2):211-218.
6. FAO/WHO: Aluminium. In : Evaluation of certain food additives and contaminants. (Thirtythird Report of the joint FAO/WHO Expert Committee on food additives.) *WHO Technical Report Series*, 1989; 776:26.
7. Garruto RM, Fukatsu R, Yanagihara R, Gajdusek D C, Hook G, Fiori C E: Imaging of Calcium and Aluminium in Neurofibrillary tangle - bearing neurons in Parkinsonism-Dementia of Guam. *Proceedings of National Academic Sciences (USA)*, 1984; 81(6): 1875-1879.
8. Ghosh, M N: Procedures for rendering animals unconscious. In: Fundamentals of experimental phamacology. 2nd Edn., Scientific Book Agency, 1984; pp 14.
9. Henry D A, Goodman WG, Nudelman RK, Didomenico ND, Alfrey A C , Slatopolsky E, Stanley T M, Coburn J W: Parenteral alumimium administration in the dog: 1. Plasma kinetics, tissue levels, Ca metabolism and parathyroid hormone. *Kidney International*, 1984; 25:362-369.
10. Neelam, Uday PK, Kaldhar M: Risk of Aluminium toxicity in Indian context. *ICMR Buletin*, 1999;29(8).
11. Perl D P: Relationship of Aluminium to Alzheimer's disease. *Environmental Health Perspective*, 1985;63: 149-153.
12. Shaver C G, Riddell A R: Lung changes associated with the manufacture of Alumina Abrasives. *Journal of Industrial Hygiene & Toxicology*, 1947; 29:145-157.
13. Smith D M: Aluminium containing dense deposit on glomerular membrane. *American Journal of Clinical, Pathology*, 1982;77:341-346.
14. Somova L 1, Missankov A, Khan MS: Chronic Aluminium intoxication in rats: Dose-dependent Morphological changes. Methodology & findings. *Experimental Clinical Pharmacology*, 1997; 19(9):599-604.
15. Sorenson J R, Campbell I R, Tepper LB, Lingg RD: Aluminium in the environment and human health. *Environmental Health Perspective*, 1974; 8:3-95.
16. Spencer A J, Wood J A, Saunders H C, Freeman M S, Lote C J: Aluminium deposition in liver and kidney following acute intravenous administration of aluminium chloride or citrate in concious rats. *Human Experimental Toxicology*, 1995;14(10): 787-794.